

VIDEOS IN CLINICAL MEDICINE

Arterial Puncture for Blood Gas Analysis

Shelly P. Dev, M.D., Melinda D. Hillmer, M.D., BSc.Ph., and Mauricio Ferri, M.D.

OVERVIEW

Radial arterial puncture for arterial blood gas analysis is a common procedure performed in adults. It is a fundamental skill that all medical trainees need to acquire.

INDICATIONS

Puncture of the radial artery is the preferred method of obtaining an arterial blood sample for blood gas analysis. The chief indication for blood gas analysis is the need to obtain values for the partial pressures of oxygen and carbon dioxide and for arterial pH. This information is needed in assessing a patient with acute, severe respiratory distress. Measurements of arterial pH and the partial pressures of carbon dioxide and oxygen provide accurate information on the status of acid-base balance and gas exchange. Another indication for arterial blood gas sampling is the need to perform CO-oximetry in order to assess for methemoglobinemia and carboxyhemoglobinemia.

CONTRAINDICATIONS

Radial arterial puncture is contraindicated in the presence of a known deficiency of collateral circulation to the distal upper extremity. A modified Allen test can be performed to assess the adequacy of the collateral circulation of the radial artery by the ulnar artery (Fig. 1). To perform the test, occlude both the ulnar and radial arteries. Instruct the patient to make a fist to drain the blood from the hand; this should be done for approximately 30 seconds. Instruct the patient to unclench the fist. The patient's palm should appear blanched or pale. Now, release pressure only from the ulnar artery. Adequate collateral circulation is indicated by the return of normal color within 10 seconds.¹

There is no agreement as to whether the Allen test can accurately predict the risk of rare ischemic complications.² On the basis of current evidence, its use can be neither refuted nor supported. Alternative techniques to measure collateral circulation of the forearm include color Doppler studies of flow, plethysmography, and magnetic resonance imaging.³ These methods are more often used in assessing the radial artery for more invasive procedures, such as arterial harvesting for coronary bypass.

Radial arterial puncture should not be performed in patients with an overlying skin infection. In patients who are taking anticoagulants or in those with coagulopathies, it should be performed only if absolutely necessary, because of the increased risk of bleeding and hematoma formation.

PREPARATION

Standard kits for sampling arterial blood gas are readily available and should contain a syringe, a small 23-to-25-gauge needle (either with a rubber stopper used to remove the needle from the syringe or with an attached safety cap), and a syringe cap containing dry lithium heparin or sodium heparin. The concentration of hepa-

From the Department of Critical Care Medicine, Sunnybrook Health Sciences Centre, University of Toronto, Toronto. Address reprint requests to Dr. Dev at the Department of Critical Care Medicine, Sunnybrook Health Sciences Centre, 2075 Bayview Ave., Suite D-112, Toronto, ON M4N 3M5, Canada.

N Engl J Med 2011;364:e7
Copyright © 2011 Massachusetts Medical Society.

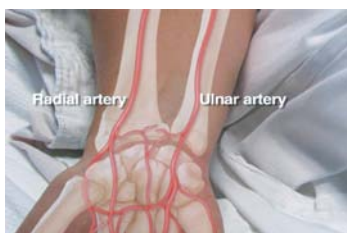


Figure 1. Location of the Radial and Ulnar Arteries.

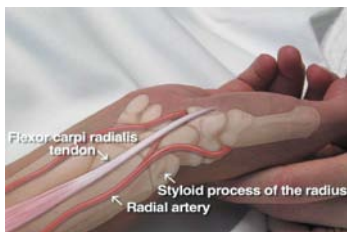


Figure 2. Location of the Flexor Carpi Radialis Tendon, the Radial Artery, and the Styloid Process of the Radius.

The radial artery is located between the tendon and the styloid process.

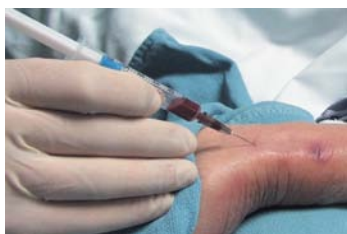

Figure 3. Puncture of the Radial Artery.

rin varies depending on the manufacturer of the kit. Alcohol swabs, gauze, tape, nonsterile gloves, and a nonsterile gown are also needed. A solution of 1% lidocaine without epinephrine can be used for local analgesia. Lidocaine can be drawn up in a 5-cc syringe and administered through a small 25-gauge needle. A rolled towel is helpful in positioning the wrist. A bag of ice may be required by the laboratory for transporting the arterial sample.

Arterial blood gas sampling often takes place in an emergency setting and may not allow for consent to be obtained from the patient or next of kin. When possible, the procedure should be explained to the patient and consent obtained.

LOCATING LANDMARKS

Before examining the patient, wash your hands in accordance with good hygienic standards. Extend the patient's wrist to bring the radial artery to a more superficial position. First, palpate the styloid process of the radius. Next, palpate the flexor carpi radialis tendon located medial to the styloid process of the radius. The radial artery is located between the styloid process of the radius and the flexor carpi radialis tendon (Fig. 2).

The artery may be difficult to palpate in some patients, such as when there is overlying edema or vasospasm. In these instances, a portable Doppler ultrasound device may be used to identify the location of the radial artery.

PROCEDURE

The patient's wrist should be extended in the supine position to bring the radial artery to a more superficial position. A rolled towel can be placed under the wrist to maintain this position. Once the wrist is positioned, put on nonsterile gloves and a nonsterile gown. Open the sampling kit and identify all the components so they are ready for use. Clean the site with an alcohol swab. Palpate the radial pulse and determine the point of maximum impulse, or use the Doppler ultrasound device to identify the location of the radial artery.

Using the 5-cc syringe and small needle, load the syringe with 1% lidocaine. When first inserting the needle under the skin, pull back on the plunger to ensure that you have not punctured a vessel. Inject a small wheal of analgesic around the artery and wait 30 to 60 seconds for the lidocaine to take effect. Relocate the maximum impulse with the index and middle fingers of your nondominant hand.

Holding the arterial blood gas syringe with your dominant hand, aim the needle away from the patient's hand toward the upper arm. Puncture the skin at a 30-to-45-degree angle at a point just below the index and middle fingers of your nondominant hand. Advance the needle slowly until the syringe easily and passively fills with bright red, pulsating blood (Fig. 3). Ideally, you should obtain at least 1 to 2 cc of blood. If no blood is obtained, do not pull back on the plunger; instead, withdraw the needle slowly until it is just under the skin and reattempt the procedure.

After the blood sample is collected, withdraw the syringe and apply pressure to the site with sterile gauze for approximately 5 minutes. In the meantime, expel the air bubbles from the syringe. Cover the needle with the attached safety cap and remove the needle from the syringe, or use the rubber stopper to remove the needle from the syringe. Attach the heparin-containing cap and, while holding the cap in place, push the plunger of the syringe to ensure the blood encounters the heparin. This will prevent the blood from clotting. Make sure that the syringe is labeled with the patient's name and unit number. If transport to the laboratory is required, place the entire syringe in the bag of ice.

Once pressure has been applied to the puncture site for 5 minutes, affix the gauze with some tape. Dispose of all sharps in designated sharps containers.

COMPLICATIONS

The most common technical difficulties associated with radial arterial puncture for arterial blood gas analysis are the failure to obtain a blood sample because of vasospasm and the collection of venous blood instead of arterial blood. If vasospasm is suspected, abort the procedure and reattempt it on the other wrist. A blood sample is likely to be venous if it is nonpulsatile and dark in color and flows slowly. It should be noted, however, that extremely deoxygenated blood in a patient with hypoxemia could also appear dark, even though it is arterial.

Serious vascular complications, such as radial arterial aneurysm, hand ischemia, and hematoma causing compartment syndrome, are rare but have been described in case reports.⁴

SUMMARY

Arterial blood gas analysis provides useful information regarding respiratory and metabolic pathology. The partial pressure of carbon dioxide, bicarbonate concentrations, and pH values indicates the presence or absence of primary or mixed respiratory and metabolic acidoses or alkaloses. The partial pressure of oxygen will reveal abnormalities in the oxygen content of blood and the presence or absence of hypoxemia. With the appropriate technique, radial arterial puncture for arterial blood gas analysis is a skill easily mastered by medical trainees. A more detailed approach to the diagnosis of acid–base disorders and hypoxemic respiratory failure, while necessary, is beyond the scope of this instructional video.

Disclosure forms provided by the authors are available with the full text of this article at NEJM.org.

REFERENCES

1. Ruengsakulrach P, Brooks M, Hare DL, Gordon I, Buxton BF. Preoperative assessment of hand circulation by means of Doppler ultrasonography and the modified Allen test. *J Thorac Cardiovasc Surg* 2001;121:526-31.
2. Barone JE, Madlinger RV. Should an Allen test be performed before radial artery cannulation? *J Trauma* 2006;61:468-70.
3. Agrifoglio M, Dainese L, Pasotti S, et al. Preoperative assessment of the radial artery for coronary artery bypass grafting: is the clinical Allen test adequate? *Ann Thorac Surg* 2005;79:570-2.
4. Halpern AA, Mochizuki R, Long CE III. Compartment syndrome of the forearm following radial-artery puncture in a patient treated with anticoagulants. *J Bone Joint Surg Am* 1978;60:1136-7. Copyright © 2011 Massachusetts Medical Society.